

Gaenslen's Split Heel Incision for Calcaneal Osteomyelitis: A case report

by J. Terrence Jose Jerome, MBBS, DNB (Ortho), MNAMS (Ortho)¹, Simon Thomas, MBBS, DNB (Ortho)², Mathew Varghese, M.S. (Ortho)³, Balu Sankaran, FRCS (C), FAMS⁴

Podiatry Internet Journal 2 (3):5

Patients who have a recurrent ulcer of the heel often have a below-the-knee amputation because durable soft tissue coverage cannot be obtained over the calcaneus. Often, even if the ulcer heals satisfactorily or the area appears to be revascularized as a result of a peripheral vascular procedure, the resulting surface is not durable and the ulcer recurs. We report a 40 year old lady who had a chronic osteomyelitis right calcaneum with a large non-healing ulcer and discharging sinus, treated by split heel incision of Gaenslen.

Chronic osteomyelitis of the os calcis presents a formidable management dilemma. Split-thickness skin grafts that are placed directly over the calcaneus occasionally can be used to cover the defect, but these grafts usually cannot withstand the forces that are generated during weight bearing. Furthermore, these patients are often poor candidates for a free tissue transfer because of underlying vascular disease or diabetes. We report a case in which Gaenslen's split-heel technique was successfully used in the management of calcaneal osteomyelitis. Gaenslen's technique is recommended for refractory cases or patients with a draining sinus centrally located on the plantar aspect of the heel. An excellent functional result can be obtained.

Case Report

A 40 year old lady with spina bifida came to our out-patient department with a large non-healing ulcer of her right heel for 3 months duration. She had consulted various doctors for the same problem, but could not get better. Her right heel showed a circular, 4 cm diameter, non-healing ulcer with seropurulent, draining sinus. (Fig. 1) The floor of the ulcer had necrotic slough and was indurated to the underlying calcaneus. The margins and edges were ill-defined. The radiograph showed a lytic lesion of the postero-inferior calcaneus with a little break in the cortex. (Fig. 2) Erythrocyte sedimentation rate was 78mm/ hour (normal <14). Her blood parameters revealed hemoglobin 11.2gms, TLC 7,500cu\mm. All other blood parameters were within normal limits.

The patient was put in the prone position with a support beneath the right ankle. A longitudinal incision exactly in the midline of the heel, extending 2.5 to 4 cm from the level of the base of the fifth metatarsal posteriorly was performed to split the end of the tendocalcaneus. The plantar fascia fascia was incised in the plane created between the abductor digiti quinti and flexor digitorum brevis. The lateral plantar artery was retracted medially and the nerve kept in the distal aspect of the wound.

Address correspondence to: Dr. J. Terrence Jose Jerome, MBBS.,DNB (Ortho), MNAMS (Ortho), FNB (Hand & Microsurgery)
Registrar in Orthopedics, Dept. of Orthopedics
St. Stephen's Hospital, Tiz Hazari, Delhi 54, India
E-mail: terrencejose@gmail.com

¹Registrar in Orthopedics, Department of Orthopedics, St. Stephens Hospital, Tiz Hazari, Delhi, India.

²Registrar in Orthopedics, Department of Orthopedics, St. Stephens Hospital, Tiz Hazari, Delhi, India.

³Head Professor, Department of Orthopedics, St. Stephens Hospital, Tiz Hazari, Delhi, India. E-mail: mathewvarghese@yahoo.com

⁴Professor Emeritus, Orthopedics, St. Stephens Hospital, Tiz Hazari, Delhi, India. E-mail: pasle@bol.net.in

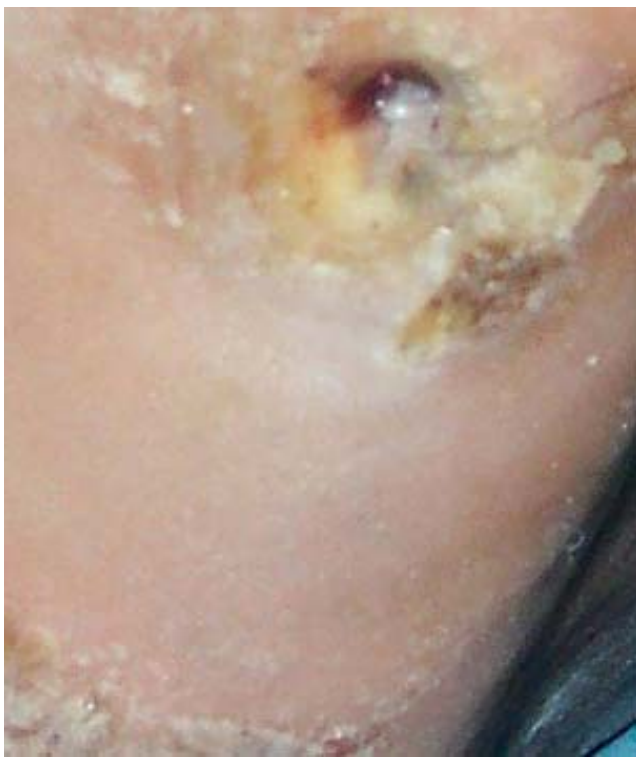
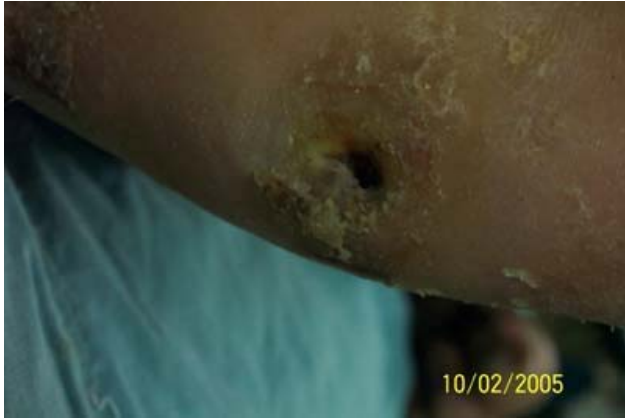
FIGURE 1 The patient's right heel showed a circular, 4 cm diameter, non-healing ulcer with seropurulent, draining sinus.

The quadratus plantae muscle and plantar ligament were split longitudinally. The calcaneus was visualized. It was divided from posterior to anterior with a broad osteotome and split into two halves to expose the interior of the bone (Fig 3). Sequestra, infected material, necrotic slough, damaged cortex were removed. Thorough lavage was given.

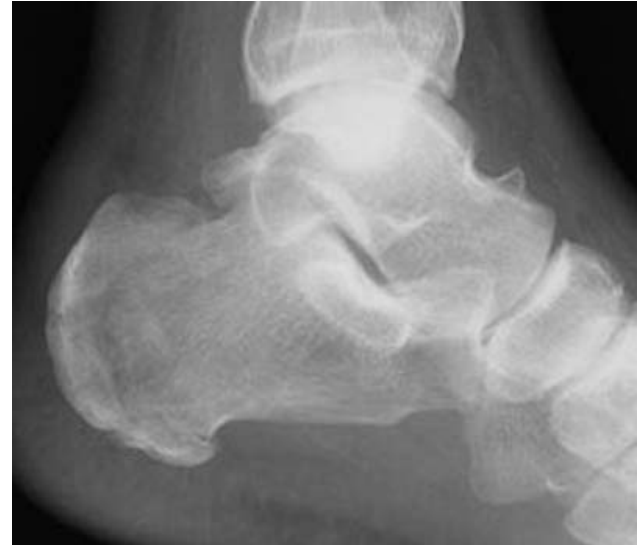

FIGURE 2 The radiograph showed a lytic lesion in the postero-inferior part with a little break in the cortex.

The wound was closed loosely with a drain in-situ. A short leg cast was applied post-operatively with the foot in neutral position and ankle at 90 degree. A window was cut over the calcaneus to permit dressing changes. Sequential dressings were done every 4th day. 2 weeks after surgery, a pressure ulcer was noted just below medial malleolus (Fig 4). Extra padding and aseptic dressing was done. After 6 weeks, the pressure sore and the surgical wound healing was remarkable (Fig 5). The heel thus developed a deeply situated surgical scar over which the surrounding tissues were laid, forming thick cushions on either side of the incision. (Fig. 6)

Discussion

In osteomyelitis of the calcaneus, as of the other tarsal bones, the destruction of the cortex usually is not very extensive. The periosteum is firmly attached to the bone, and is usually perforated rather than elevated by purulent material; therefore the formation of involucrum is minimal¹.

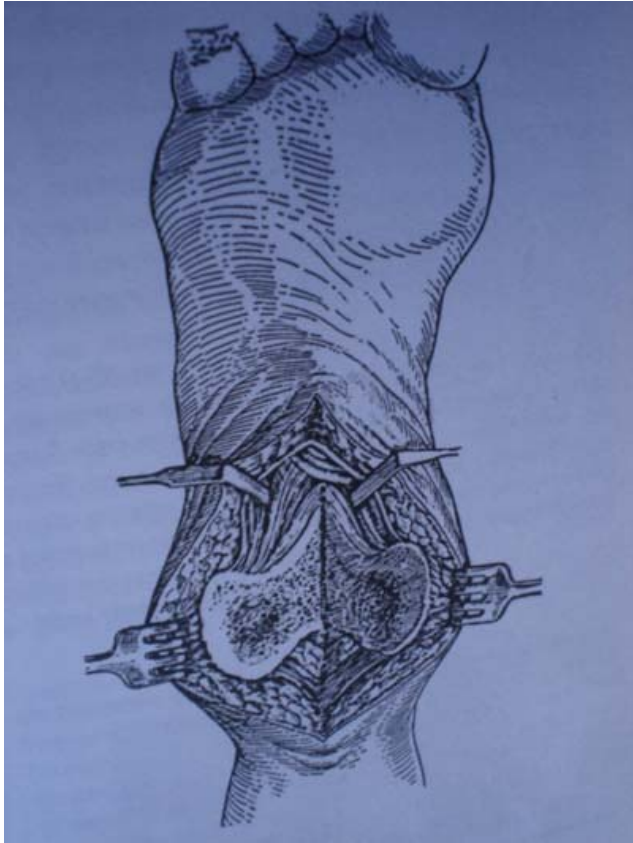


FIGURE 3 The Gaenslen approach uses a broad osteotome and splits the calcaneus into two halves to expose the interior of the bone.

Partial calcaneotomy is not a new procedure. Four reports, between 1931 and 1959, discussed resection of all or part of the calcaneus for the treatment of conditions as diverse as osteomyelitis of the calcaneus, cutaneous ulceration of the heel, and fracture of the calcaneus^{2,3,4}. These authors reported that all of the patients were managed successfully and maintained their functional mobility. Reports published between 1972 and 1991 also documented favorable results^{1,5,6,7}. However, partial calcaneotomy has not received much attention, and it seems that surgeons are often unaware that it is an option for the management of large ulcerations of the heel or osteomyelitis of the calcaneus.

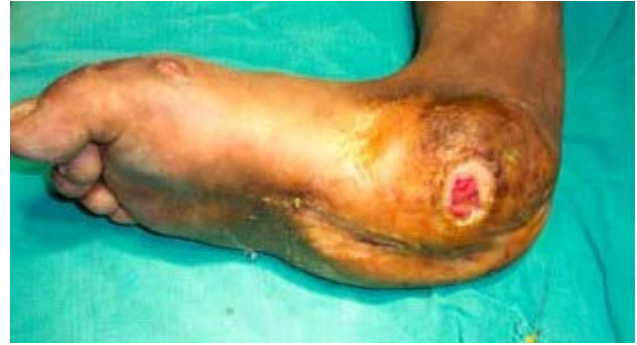

FIGURE 4 2 weeks after surgery, a small pressure ulcer developed just below the medial malleolus.

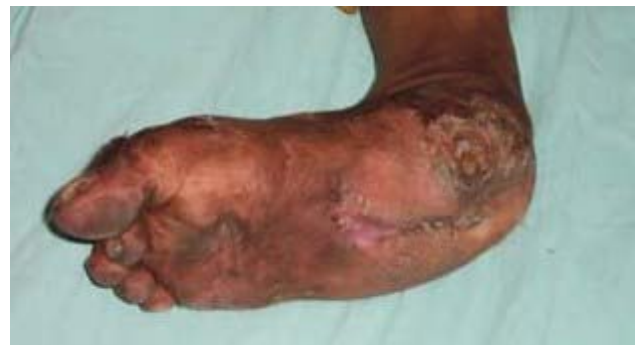

FIGURE 5 The surgical and pressure wounds healed without incident.

Total calcaneotomy is an alternative procedure to trans-tibial amputation in patients with chronic osteomyelitis of the calcaneus. Eradication of infection and preservation of functional ambulation is achieved⁸. Assessment of ankle strength and range of motion of the surgical limb demonstrated decreased dorsiflexion and plantarflexion strength and variable range of motion compared to the contralateral limb⁸. The split-heel technique was successfully used in the management of calcaneal osteomyelitis in children. Antibiotic therapy and debridement when necessary through medial or lateral incisions will usually eradicate the infection.

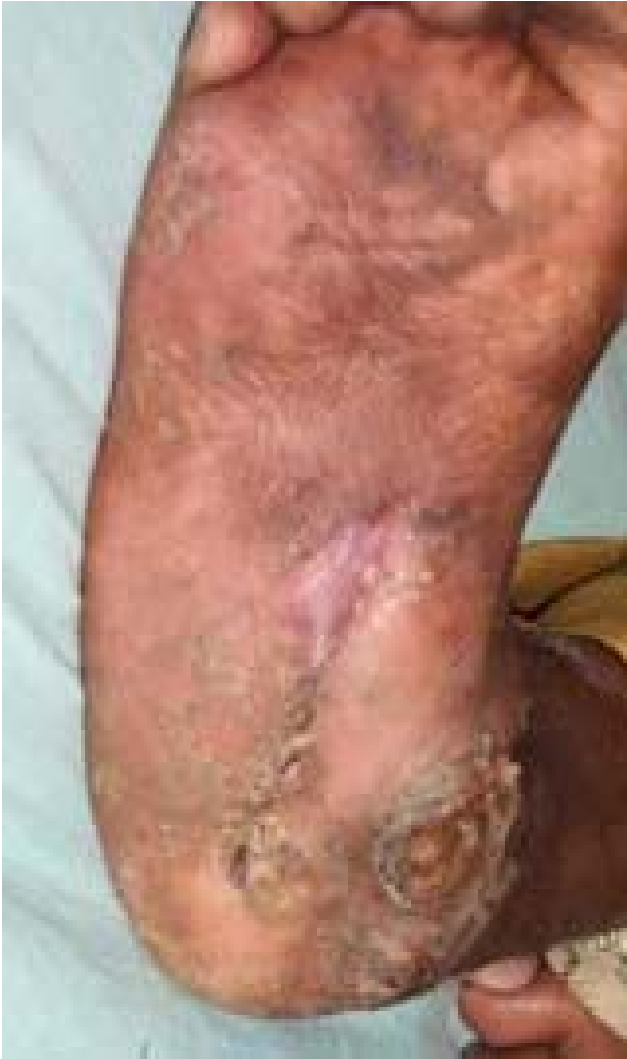

FIGURE 6 The heel develops a deeply situated surgical scar over which the surrounding tissues were laid, forming thick cushions on either side of the incision.

Gaenslen's technique is recommended for refractory cases or patients with a draining sinus centrally located on the plantar aspect of the heel. In general, excision of the calcaneus for chronic osteomyelitis in children is not necessary⁹. The resultant scars usually are painless. They are so deeply situated that the tissues on either side curl inward.

Diabetic, neuropathic patients are often at risk for ulceration. Those that are temporarily or permanently limited in ambulation and restricted to a supine position are, over time, very susceptible to heel decubiti. Subtotal calcaneotomy is a relatively simple procedure to perform. Aggressive debridement of all nonviable tissue, thorough antibiotic course, ankle-foot orthosis combined with a custom-molded shoe in the postoperative period made all patients who were ambulatory preoperatively to resume their function after surgery¹⁰. In the presence of adequate vasculature, it is a good alternative to below-the-knee amputation and the accompanying sequelae. Composite wounds of the heel with secondary osteomyelitis of the calcaneus remain a reconstructive challenge. A paucity of regional flaps has often necessitated microvascular transplantation in order to obtain wound healing. Subtotal calcaneotomy, traditionally a technique of the orthopedic surgeon, can, in selected cases, eradicate infection and achieve wound closure and limb preservation¹¹.

A distally based sural fascio-musculocutaneous flap including the sural nerve and a midline cuff of the gastrocnemius muscle can be useful for covering the defect. This flap is designed on the proximal half of the posterior calf and has an adequate blood supply derived from retrograde perfusion of the vascular axis of the sural nerve to the musculocutaneous perforators of the gastrocnemius muscle. The patency of the peroneal artery should be confirmed by doppler ultrasound or angiography before surgery¹². The flap was reliable and technically simple to design and execute. This 1-stage procedure not only preserves the major arteries of the injured leg but has also proved valuable for filling bony defect and treating bony infection because it provides a well-vascularized muscle fragment.

Conclusion

Our patient had a large non-healing plantar ulcer with discharging sinus along with chronic calcaneal osteomyelitis. Split heel incision of Gaenslen removed all sequestra, obviously infected matter and did little damage to the cortex. The resultant scar was painless and was so deeply situated that the tissues on either side curl inward to form 'cushions'. Gaenslen's technique is recommended for refractory cases of osteomyelitis or patients with a draining sinus centrally located on the plantar aspect of the heel. An excellent functional result can be obtained.

References

1. Antoniou D, Conner AN: Osteomyelitis of the calcaneus and talus. *J Bone Joint Surg* 56A:338,1974
2. Gaenslen, F. J.: Split-heel approach in osteomyelitis of os calcis. *J. Bone joint Surg.*, 13: 759-772, Oct. 1931.
3. Wiltse, L. L.; Bateman, J. G.; and Kase, Sidney: Resection of major portion of the calcaneus. *Clin. Orthop.* 13: 271-278. 1959.
4. Wolf, T. S., and Beals, R. K.: Partial calcaneotomy for the treatment of osteomyelitis of the calcaneus. *Foot and Ankle*, 12: 31-34, 1991.
5. Crandall, R. C., and Wagner, F. W., Jr.: Partial and total calcaneotomy. A review of thirty-one consecutive cases over a ten-year period. *J. Bone Joint Surg.*, 63-A: 152-155. Jan. 1981.
6. Horwitz, T.: Partial resection of the os calcis and primary closure in the treatment of resistant large ulcers of the heel with or without osteomyelitis of the os calcis. *Clin. Orthop.* 84: 149-153. 1972.
7. Martini, M.; Martini-Benkeddache, Y.; Bekhechi, T.; and Daoud, A.: Treatment of chronic osteomyelitis of the calcaneus by resection of the calcaneus. A report of twenty cases. *J Bone Joint Surg.* 56-A: 542-548, April 1974.
8. Baumhauer JF, Fraga CJ, Gould JS, Johnson JE: Total calcaneotomy for the treatment of chronic osteomyelitis. *Foot Ankle* 19:849,1948
9. Broudy AS, Scott RD, Watts HG: The split heel technique in the management of calcaneal osteomyelitis in children. Report of three cases. *Clin Orthop Relat Res.* 1976 Sep;(119):202-5
10. Baravarian B, Menendez MM, Weinheimer DJ, Lowery C, Kosanovich R, Vidt L: subtotal calcaneotomy for the treatment of large heel ulceration and calcaneal osteomyelitis in the diabetic patient. *J Foot Ankle Surg.* 1999 Sep-Oct;38(5):373-4.
11. Isenberg JS, Costigan WM, Thordarson DB: Subtotal calcaneotomy for osteomyelitis of the os calcis: a reasonable alternative to free tissue transfer. *Ann Plast Surg.* 1995 Dec;35(6):660-3.
12. Chen SL, Chen TM, Chou TD, Chang SC, Wang HJ: Distally based sural fascio musculo cutaneous flap for chronic osteomyelitis in diabetic patients. *Ann Plast Surg.* 2005 Jan;54(1):44-8